

Extensive **implant**-supported restoration in generalised aggressive periodontitis

Author_Dr Dr Philipp Plugmann, Germany

Introduction

Particularly young patients under the age of 30 experience high levels of psychological strain when faced with episodic loss of several teeth as a result of generalised aggressive periodontitis. The influence of this disease on the patients' social life and their careers can be enormous.

Case presentation

In February of 2012, the patient presented in my practice at the age of 28. Despite his young age, he had already lost several teeth. The probing pocket depth was 3.5–5 mm, the plaque control record (PCR) was at 100 % and the gingival bleeding index (GBI) was at 90 %. Several different treatments were necessary: teeth 21 and 23 needed endodontic treatment and root canal fillings, a long-term temporary restoration was necessary for teeth 21 to 23, and a ceramic inlay was indicated for tooth 46. In addition, the patient suffered from halitosis. The combination of the symptoms proved a great burden on the patient.

The patient described an episodic loss of teeth in the course of the past four years and a family history

of tooth loss starting at the early ages of 20 to 25. The patient smokes. The patient was healthy otherwise and there were no further pathological findings.

The patient gave up smoking in March of 2012 and improved his oral hygiene, thereby lowering the PCR to 12 % and the GBI to 8 % and permanently establishing them below a value of 10–15 %. The preservative treatment was finished and the treatment of the periodontitis was concluded with a closed curettage.

During regular follow-up care, the patient received supporting periodontitis therapy and showed excellent compliance. In March of 2013, we started to plan an implant-supported restoration.

The patient's oral situation before proceeding: Multiple gaps in the upper and lower jaw. Additionally, a terminal gap can be seen at the far end of the upper jaw (right side on the patient). Good amount of bone available in the posterior tooth area. Less bone available in the upper incisal area. The presurgical panorama X-ray shows the initial situation before the implantation (Fig. 1). The implants were inserted in March of 2013.

Fig. 1 Presurgical panorama X-ray.

Fig. 2 Flap exposing the surgical field, first quadrant.

Fig. 3 Display of the vestibular bone structure, first quadrant.

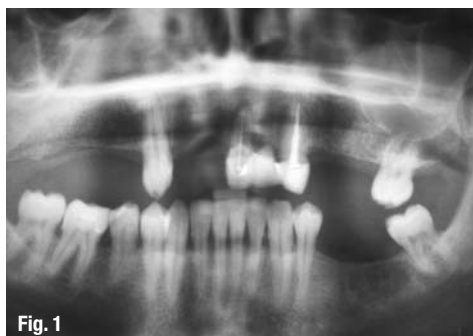

Fig. 1

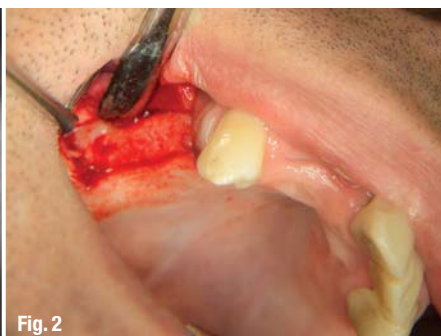

Fig. 2

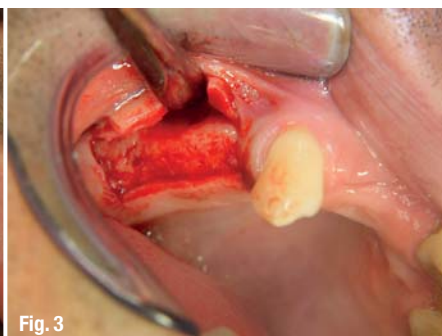


Fig. 3

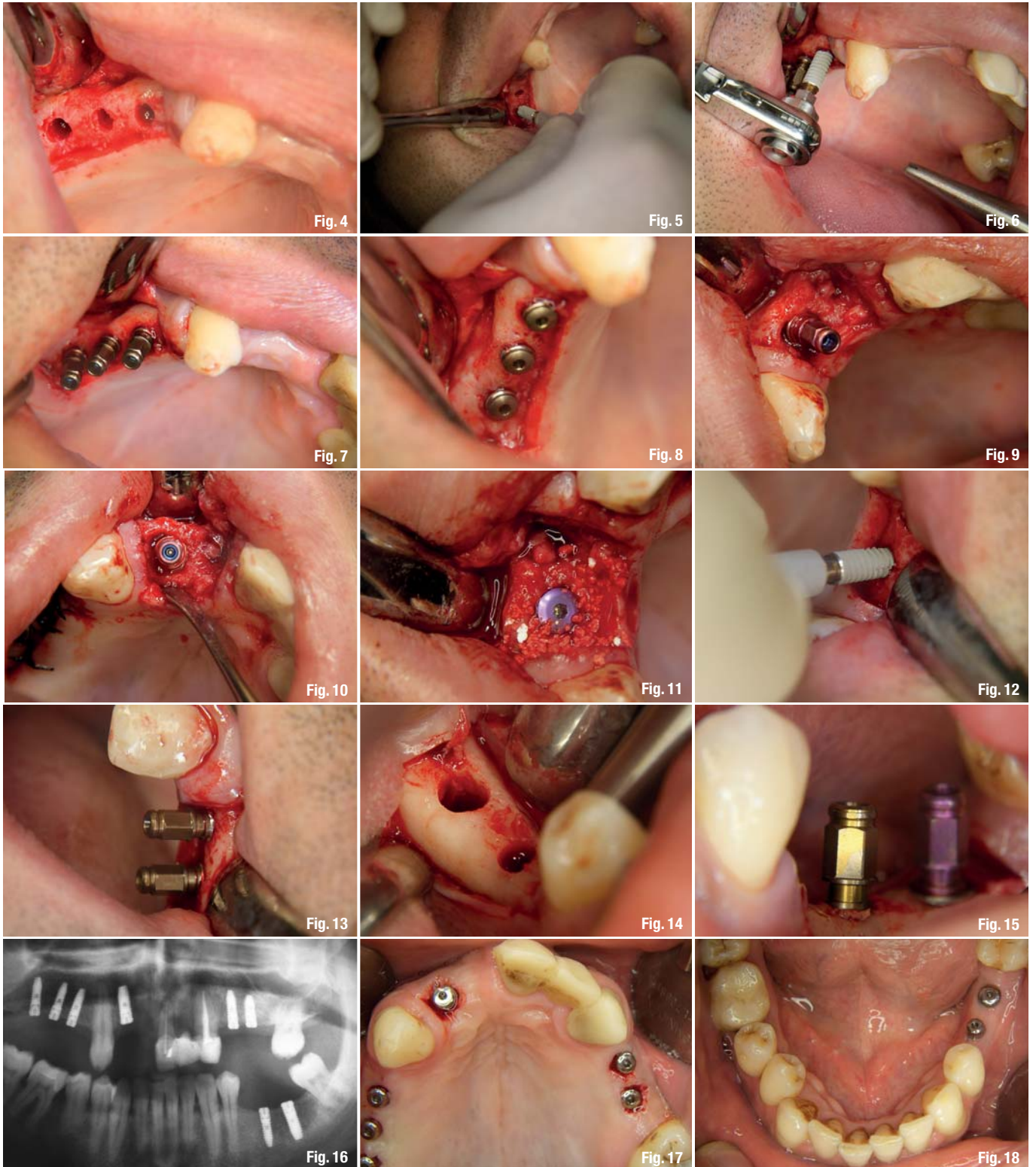


Fig. 4 Prepared implant bed, positions 14, 15 and 16.

Fig. 5 First step, manually screwing the implant in.

Fig. 6 Second step, further screwing in with the adjustable IMPLA ratchet, 30 Ncm for primary stability.

Fig. 7 Insertion posts on top of the implants, positions 14, 15 and 16.

Fig. 8 Healing caps in positions 14, 15 and 16.

Fig. 9 Inserted implant with insertion post, position 12.

Fig. 10 View of the bone situation.

Fig. 11 Implant with a healing screw and bone augmentation material.

Fig. 12 Screwing the implant into position 25.

Fig. 13 Parallel implants with insertion posts in positions 24 and 25.

Fig. 14 Implant bed, positions 35 and 36.

Fig. 15 Implants with insertion posts, positions 35 and 36.

Fig. 16 Postsurgical panorama X-ray.

Figs. 17 & 18 Insertion of gingival formers.

Figs. 19–21_Unscrewing of the forming posts and inner screws for the impressions.

Figs. 22–26_Placing of the abutment onto the model.

Fig. 27_Panoramic X-ray with abutments.

Figs. 28–30_Permanently fixed restoration.



Fig. 19

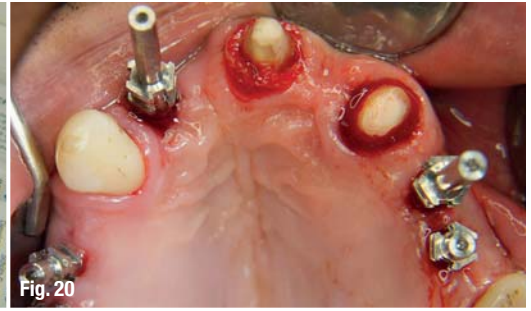

Fig. 20

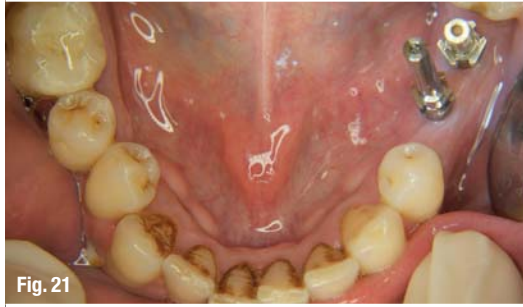

Fig. 21

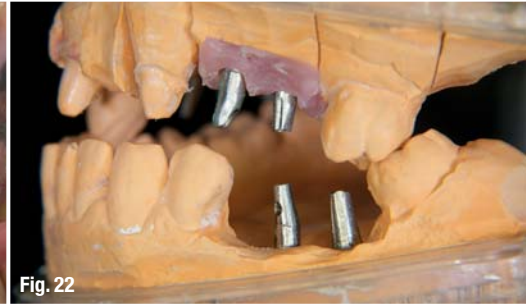

Fig. 22

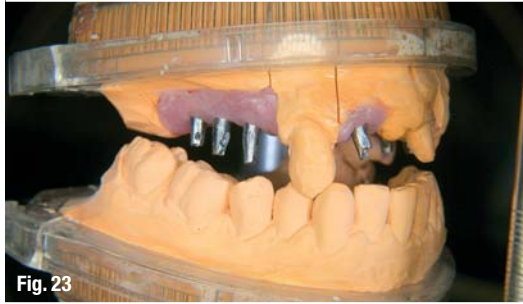

Fig. 23

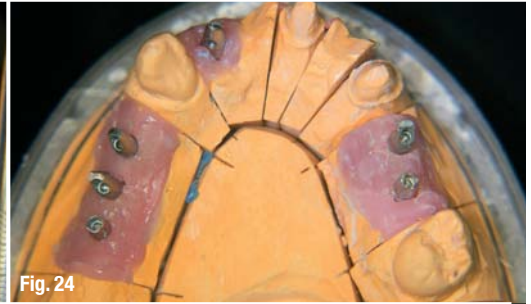


Fig. 24

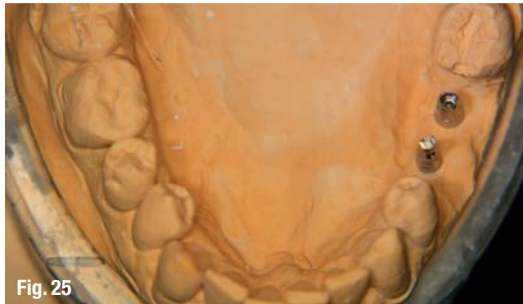


Fig. 25

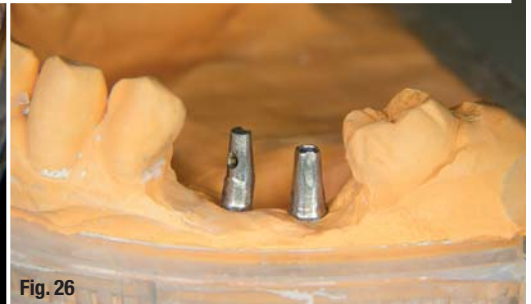

Fig. 26

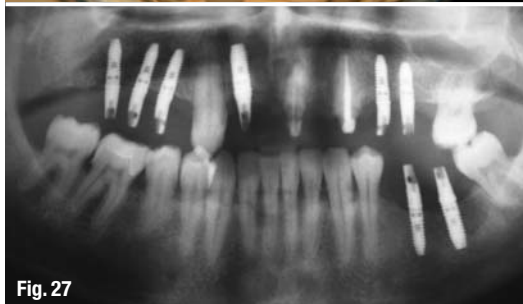


Fig. 27

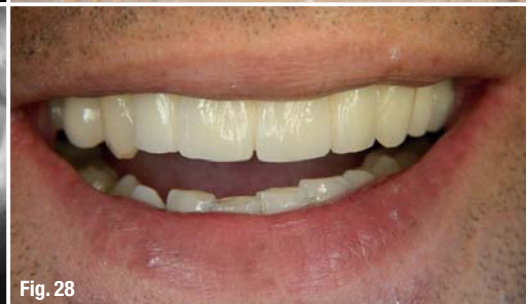

Fig. 28

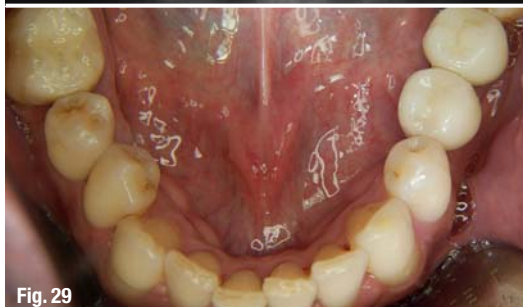

Fig. 29

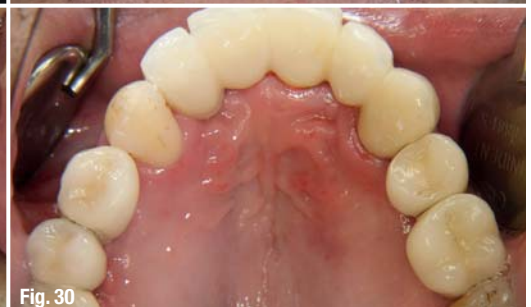

Fig. 30

_Surgical procedure

First, I exposed the bone using a scalpel and a sharp curette. Because this case deals with a D4 bone, I decided to use an IMPLA Cylindrical implant from Schütz Dental. Thanks to the cylindrical structure and especially coordinated thread sides, this implant offers a high primary stability in cases such as this one (Figs. 2–4).

Thanks to the self-tapping thread of IMPLA Cylindrical implant, I only had to apply the pilot and extension drilling techniques. With the help of the acrylic insertion aid and "no-touch" technology, I could insert and screw the implants quickly and easily into the drill holes (Figs. 5–7).

After taking off the insertion posts and screwing on the healing caps, the mucous membrane was fitted with several 4.0 interrupted sutures (Ethicon, braided silk, non-absorbable, Fig. 8). While I was exposing the bone in position 12, I noticed that the available bone structure would not be sufficient (Fig. 9).

Here, I chose an augmentative bone construction using the bone augmentation material CERASORB from the company Riemser as well as a resorbable Epiguide membrane. After I inserted the implant and screwed on the healing cap, I remodelled the bone structure using bone augmentation material. This made sure that the neck of the implant wouldn't be seen after surgery (Figs. 10–13). After inserting the implants and removing the insertion posts, the implants were sealed with the healing caps.

While treating the lower jaw, I came across a D1 bone. Once again, I chose to use the IMPLA Cylindrical implant, only this time for its self-tapping properties. This made the screwing in of the implant so much easier in such compact bone as this (Figs. 14 and 15). The postsurgical panorama X-ray shows the situation with the inserted implants (Fig. 16).

_Implant prosthetics

In September of 2013, six months after implantation, the implants in the upper and lower jaw were exposed. Then, the appropriate gingiva formers in gingiva heights 2 and 3 were inserted (Figs. 17 and 18).

Subsequently, alginate impressions were taken to produce plaster models and individual impression trays. The individual impression trays were to serve for individual impressions with impression posts and the posts 21 and 23 to be prepared. The forming posts and according inner screws for the impressions were unscrewed directly after removing them from the pack-

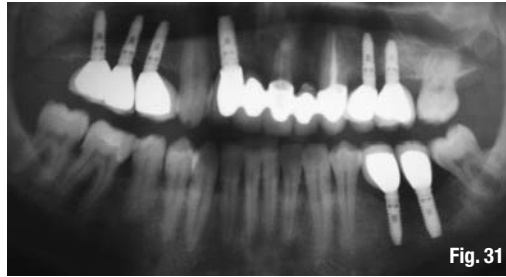

Fig. 31 Panoramic X-ray of the final result.

age (Figs. 19–21). Afterwards, an extensive function analysis and function diagnostics were performed.

At our own lab, the necessary models were produced from the impressions, taking into account the results of the function diagnostics. Next, the models were articulated. Finally, the designated abutment were screwed onto the model and worked on (Figs. 22–26).

During the next session, the implant abutments and the framework were fitted intraorally. The fit of the abutments was additionally documented by and checked with a panorama X-ray (Fig. 27, panorama X-ray with abutments). At a later date, the abutments were screwed in permanently and the openings were covered with Cavit.

The restoration was set in for a test period of two weeks. At the end of September, the restoration was permanently fixed (Figs. 28–30).

Finally, a panorama X-ray was taken for documentation and to check the result (Fig. 31).

_Conclusion

When dealing with major tooth loss after a generalised aggressive periodontitis, implant-supported individual crowns are an excellent solution, as they offer the patient optimal possibilities for oral hygiene. First, however, a complex and tedious pre-treatment phase is necessary, as only a highly motivated and contributory patient, who will show up to each follow-up care session, can avoid a recidivism and complications of peri implantitis in the long run.

_contact

implants

Dr Dr Philipp Plugmann, MSc MSc MBA

Doctor of Dental Medicine (DMD)

Master of Science Periodontology and

Implant Therapy (DGParo)

Ludwig-Erhard-Platz 1

51373 Leverkusen, Germany